

## Pancoast syndrome: A case report.

Dr. Amit Bhandari<sup>1\*</sup>, Dr. Pooja Prajapati<sup>2</sup>, Dr. Vasant Rathod<sup>3</sup>

<sup>1,2</sup> Resident Doctor, <sup>3</sup> Assistant Professor, Department of Radiology, B. J. Medical College, Civil Hospital, Ahmedabad, Gujarat, India.

### Abstract:

Pancoast tumor (Superior sulcus tumor) is associated in most cases with a poor clinical outcome. Due to its localization in the apex of the lung, it has a potential of invasion of the lower part of the brachial plexus, first ribs, vertebrae, subclavian vessels or stellate ganglion. Multimodality therapy with irradiation, chemotherapy, and surgery offers the best possibility for long-term survival and cure in most cases. To accurately determine tumor resectability and to help optimize the treatment, radiologists need a detailed knowledge of the clinical and imaging manifestations of disease.

**Key words:** Brachial plexus, Imaging, Pancoast tumor, Superior sulcus tumor.

### Introduction:

Pancoast syndrome is a set of signs & symptoms secondary to the neoplastic impairment of the brachial plexus, parietal pleura, first/second ribs (and adjacent vertebral bodies), first/second thoracic nerves, paravertebral sympathetic chain and stellate ganglion, due to a tumor in the superior sulcus, also known as a Pancoast tumor. Clinically, the symptoms are pain in the shoulder and ipsilateral affected arm progressing to weakness and muscle hypotrophy. Horner's syndrome, which involves stellate ganglion impairment, clinically manifesting as ptosis, miosis, enophthalmos and ipsilateral anhidrosis, can be included in the spectrum of Pancoast syndrome features. Most patients with Pancoast tumors have non-small cell bronchogenic carcinoma, most often squamous / adenocarcinoma. The objective of this report is to discuss the clinical presentation, imaging presentation & role of imaging in the diagnosis, determining the extent of involvement and further management of this condition.

### Case Report:

A 55year old male patient presented in Orthopaedic OPD with complaints of right shoulder pain radiating to arm. He also had complaint of cough occasionally. There was no history of fever, trauma or heavy weight lifting. Patient also had the history of chronic smoking since 40 years.

On Examination, patient had drooping of right upper eyelid and constriction of right pupil. [Image 1]

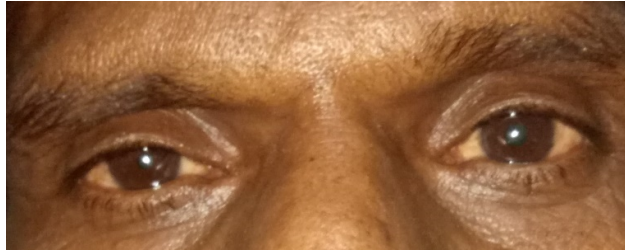#### \* Corresponding Author:

Dr. Amit Bhandari

E-mail: [bhandariamit92@gmail.com](mailto:bhandariamit92@gmail.com)

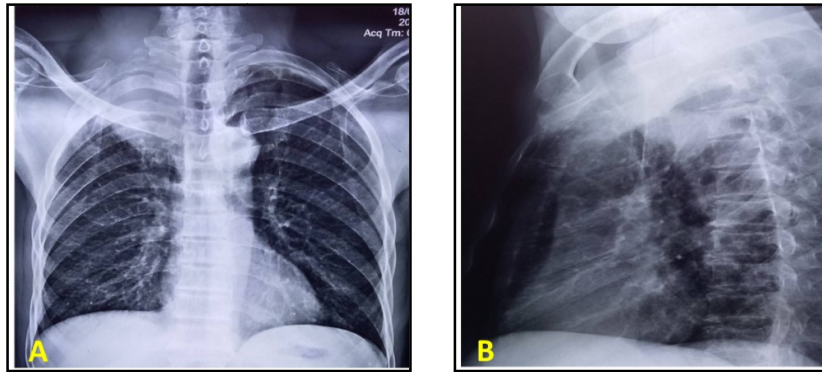
#### QR Code:



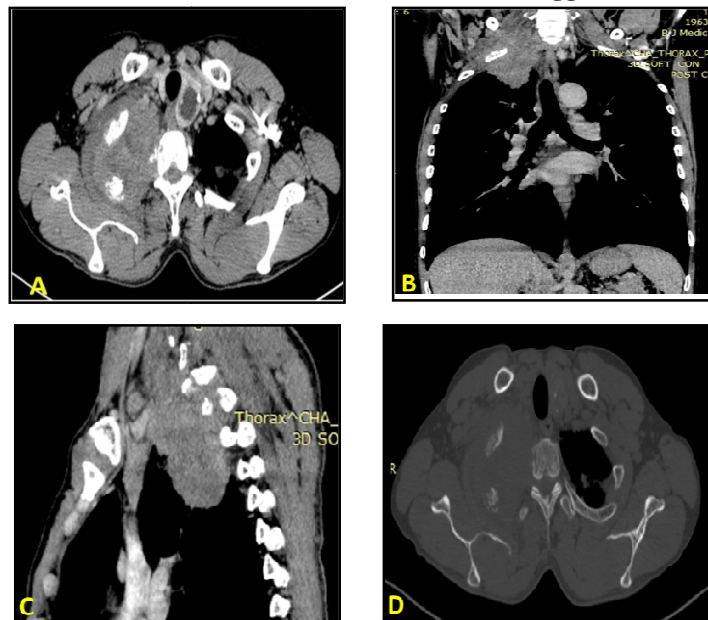
**Image 1 Drooping of right eyelid.**

He was advised X-ray Right Shoulder AP and lateral view & X-ray chest PA and lateral view. Chest X-ray revealed presence of abnormal ill defined soft tissue opacity in right upper zone extending into lower aspect of neck & erosions of 1<sup>st</sup> and 2<sup>nd</sup> rib. [Image 2]

**Image 2 Chest x-ray - showing ill defined soft tissue opacity in right upper zone**  
(A) PA View (B) Lateral view



**Image 3 CECT-Thorax showing mass lesion in apical segment of right upper lobe with extra-thoracic extension. (A) Axial section (B) Coronal section (C) Saggital section (D) Bony window**



Then patient was subjected to CECT thorax. CECT Thorax revealed presence of approximately 7x8x8 cm sized heterogeneously enhancing mass lesion in apical segment of

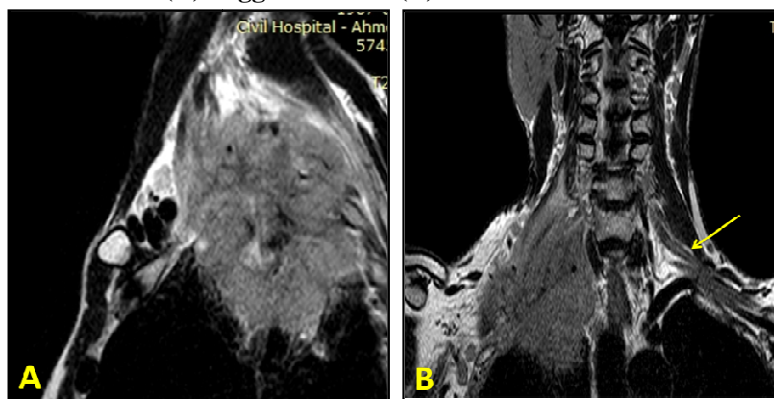
right upper lobe extending into lower aspect of right side of neck. The lesion causes erosion of 1<sup>st</sup> and 2<sup>nd</sup> ribs. The lesion shows extra-thoracic extension upto C7 vertebral level and invades right sided longus colli, scalene muscles, spinal cervices and semispinalis capitis. It encases thyrocervical trunk and displaces right subclavian artery anteriorly. Multiple enlarged enhancing right hilar, mediastinal, supraclavicular lymphnodes were seen. [Image 3]

Further, MRI brachial plexus was done which revealed presence of mass lesion in right lower aspect of neck with presence of abnormal T2 hyperintensity along right brachial plexus and non visualisation of cords separately suggestive of invasion by the mass lesion. [Image 4]

**Image 4: MRI brachial plexus T2WI - showing mass lesion in right lower aspect of neck.**

**(Arrow indicate Normal brachial plexus on left side)**

**(A) Saggital section (B) Coronal section**



These findings were suggestive of malignant mass of right upper lobe with extra-thoracic extension into muscles of neck, involvement of brachial plexus on right side and erosions of right 1<sup>st</sup> & 2<sup>nd</sup> rib and metastatic lymphadenopathy. Imaging features with clinical presentation of the patient made the diagnosis of Pancoast Syndrome.

CT guided FNAC of the lesion was done which revealed squamous cell carcinoma. Patient has currently been started on combination of chemotherapy and radiotherapy.

### **Discussion:**

Pancoast tumors are non-small cell carcinomas. They originate in the lung apex and cause signs and symptoms known collectively as Pancoast syndrome.<sup>[1]</sup>

Adenocarcinomas account for 2/3 of all Pancoast tumors, while the rest of the tumors are squamous cell and large cell carcinomas.<sup>[2]</sup>

They invade through tissue contiguity the apical chest wall and the structures of the thoracic inlet (parietal pleura, 1st and 2nd ribs or periosteum and adjacent 1st and 2nd vertebral bodies, the lower nerve roots of the brachial plexus, the upper sympathetic chain and stellate ganglion, the subclavian vein and artery), producing a clinical picture known as Pancoast syndrome.<sup>[2]</sup>

The clinical features include pain in the shoulder girdle and arm<sup>[2]</sup> and Horner syndrome (miosis, ptosis and ipsilateral anhidrosis of the face with narrowing of the palpebral

fissure secondary to paralysis of the Müller muscle – due to invasion of the cervical sympathetic ganglion).<sup>[1,3,6]</sup>

Clinical History and examination of the patient provides the first clue. Chest X-ray is the first line investigation and screening test for the evaluation of the Pancoast tumour.<sup>[5]</sup>

CT is considered in the assessment of evaluation of the loco-regional extension, chest wall invasion, nodes involvement and distant metastasis.<sup>[4]</sup>

For evaluation of loco-regional extension (particularly brachial plexus, subclavian vessels, parietal pleura, subpleural fat, neurovertebral foramina, and spinal canal), MR provides a higher soft tissue resolution compared to CT.<sup>[4,6]</sup>

Treatment depends crucially on the extent of involvement, as these lesions usually involve the brachial plexus and subclavian vessels.<sup>[1,3]</sup>

### Conclusion:

Imaging has a crucial role for staging & therapeutic management of the patient with Pancoast tumor. Informations which are obtained from CT combined with MRI are necessary to rule out close and complex relationships among anatomic structures in thoracic inlet. Patient's symptoms & imaging findings help us to make up the correct diagnosis and its appropriate management.

### References:

1. J. F. Bruzzi, R. Komaki, G. L. Walsh et al. Imaging of non-small cell lung cancer of the superior sulcus. *Radiographics*, vol. 28, no. 2, pp. 561–572, 2008.
2. Foroulis, Christophoros N. et al. “Superior sulcus (Pancoast) tumors: Current evidence on diagnosis and Radical treatment.” *Journal of Thoracic Disease* 5.Suppl 4 (2013): S342–S358. *PMC*. Web. 17 July 2018.
3. Marulli G, Battistella L, Mammana M, Calabrese F, Rea F. Superior sulcus tumors (Pancoast tumors). *Annals of Translational Medicine*. 2016;4(12):239. 2016.06.16.
4. Guglielmo Manenti, Mario Raguso, Silvia D'Onofrio, et al., “Pancoast Tumor: The Role of Magnetic Resonance Imaging,” *Case Reports in Radiology*, vol. 2013, Article ID 479120, 5 pages, 2013.
5. John R. Haaga; *CT and MRI of the whole body* 5<sup>th</sup> edition. ELSEVIER. 2009 pp 941.942,1060.
6. W. Richard Webb, Charles B. Higgins; *Thoracic Imaging Pulmonary and cardiovascular imaging* 2<sup>nd</sup> edition. Wolters Kluwer Lippincott Williams &Wilkins, 2011 pp 79-81.